

Score of Multi Parametric MRI: T2 and DWI to Assist Prostate Cancer Detection

by Tjondro Setiawan

Submission date: 15-Apr-2021 10:51AM (UTC+0700)

Submission ID: 1559657280

File name: 02._Score_of_Multi_Parametric_MRI_to_Assist_Prostate_Ca.pdf (581.54K)

Word count: 5386

Character count: 27910

Score of Multi Parametric MRI: T2 and DWI to Assist Prostate Cancer Detection

Tjondro Setiawan^{1*}, Bachtiar Murtala^{1**}, Andi Fachruddin Benyamin^{2**}, Mochammad Hatta^{3**}, Ali Suyono Purwita^{4*}, Taufan Tenggara^{4*}, Egi Edward Manuputty^{4*}, Gatot Susilo Lawrence^{5**}

¹Radiology Department, ²Internal Medicine Department, ³Microbiology Department,

⁴Urology Department, ⁵Pathology Anatomy Department,

Gading Pluit Hospital-Jakarta,

^{**}Hasanuddin University-Makassar,

Corresponding Author: Tjondro Setiawan

50

ABSTRACT

Purpose: The purpose of this study is to utilize simpler multi parametric Magnetic Resonance Imaging (mp-MRI): T2 Weighted Image (T2WI) and Diffusion Weighted Image (DWI) for prostate cancer detection without contrast injection.

Methods: This cross section study evaluated 19 patients whom met inclusion and exclusion criteria. The prostate mp-MRI used pelvic phased array surface coil and endorectal coil. Category evaluation in T2WI and DWI sequence based on PIRADS version 2 standard, while ADC value as a complementary added value derived from DWI sequence by pointing the specified Region of Interest (ROI). The score and value results were analyzed statistically with Mann Whitney U test to know whether the results could differentiate prostate cancer with benign prostate. Cut off points were defined using Receiver Operating Curve (ROC).

Results: The mp-MRI median score for prostate cancer and benign prostate were 9 (8:10), 2 (2:9) respectively while ADC median value for prostate cancer and benign prostate were 0.542 (0.339:0.768), 0.987 (0.390:1.569). There was a significant difference between prostate cancer and benign prostate score ($p=0.005$, $p<0.05$), there was also a significant difference between ADC value for prostate cancer and benign prostate ($p=0.022$, $p<0.05$). Cut off point of 7 for mp-MRI score has 100% sensitivity and 71.4% specificity while ADC value cut off of 0.684 has 71.4% sensitivity and 91.7% specificity.

Conclusion: This simpler mp-MRI is able to differentiate prostate cancer from benign prostate. Using mp-MRI score cut off 7, it has good sensitivity also specificity and since it is simpler, it might be applicable and helpful for prostate cancer detection complemented by ADC value. Due to small sample number; therefore, further studies are needed to validate this research.

Keywords: Prostate cancer - multi parametric MRI – ADC – non contrast – score

INTRODUCTION

Prostate cancer is the second most common cancer in men, it was estimated that 1.1 million men worldwide were diagnosed with prostate cancer in 2012 and 70% of the cases occurred in more developed countries. ⁽¹⁾ The risk of a man to be diagnosed with cancer prostate is 1 out of

6 men, while the mortality risk is 1 out of 35 men. ⁽²⁾

The standardized and widely accepted prostate cancer detection modality for patients with prostate abnormalities based from European Association of Urology (EAU), American Urological Association (AUA), National Comprehensive Cancer Network (NCCN) also National Institute for

Health and Clinical Excellence (NICE) are from history or patient complaints/symptoms, Digital Rectal Examination (DRE), and Prostate Specific Antigen (PSA) lab test with diagnostic establishment by histopathology findings.⁽³⁻⁶⁾ Even so, there are risks of unnecessary biopsies that eventually will increase logistic loads, morbidity also psychological burdens for the patients.⁽⁷⁾ The incidence and prevalence of prostatitis and Benign Prostate Hyperplasia (BPH) in Asian countries are comparable to Western countries, but are not the same for prostate cancer. The prostate cancer incidence is much lower in Asian countries. Therefore, considering low incidence of prostate cancer, there should be different and wise perspectives about the interpretation of elevated PSA in Asian countries for prostate cancer detection.^(8,9)

MRI is the chosen imaging modality in this research because it has all the strengths needed and without radiation exposure. The strengths of MRI are its high soft tissue contrast and characterization, its multi parametric image acquisition, its multiplanar imaging capability, and the advanced computational methods to assess function. Moreover, it can be performed without intravenous contrast administration, allowing more patients with medical limitations, such as kidney problems or allergy to undergo this procedure and more comfortable for screening purpose. Resolution of MRI images in the pelvis can be augmented using an endorectal coil.⁽¹⁰⁾ It helps clinicians, especially in tough anatomical position such as apex and anterior gland, that may not be reached even with extended biopsy method. MRI is effective for studying the anterior and posterior regions of the prostate in patients presenting lesions suspected of being neoplastic.⁽¹¹⁻¹⁴⁾

Mp-MRI images are defined as images acquired with at least one more sequence in addition to the anatomical T2-weighted images.⁽¹⁰⁾ This research used T2WI and Diffusion Weighted Image

(DWI) sequences, without Dynamic Contrast Enhancement (DCE) sequence to avoid contrast injection with shorter acquisition time. DWI is a functional imaging technique that quantifies random water molecule Brownian movement in the tissue. Net displacement of the molecules is called Apparent Diffusion Coefficient (ADC).⁽¹⁵⁾ Cancer tissue has increasing signal intensity on high-*b*-value Diffusion-Weighted Images than healthy prostate tissue, that will result in decreased ADC values.^(16,17)

Recently, DCE role has been questioned given a view by some experts that findings from DCE-MRI may enhance tumor detection compared with findings from the combination of T2WI and DWI but in less than 20% of cases.⁽¹⁸⁾ DCE-MRI improved tumor detection compared to T2WI, but it did not clearly raise performance compared with the combination of T2WI and DWI.⁽¹⁹⁾ Therefore, we believe that simpler MRI protocol with T2WI and DWI without DCE may be sufficient for tumor detection and could be used to differentiate malignancy.

Through this study, we will find out whether this simpler non contrast mp-MRI could differentiate prostate cancer and benign prostate, define the cut off points of the mp-MRI score and ADC value along with their diagnostic parameters.

RESEARCH DESIGN and METHODS

Seventy (70) patients were referred to Gading Pluit Hospital Radiology Department with prostate cancer suspicion to do prostate mp-MRI. Prior of the referral, patients were examined thoroughly by urologists and underwent laboratory tests that are considered necessary. All the patients consecutively underwent the MRI exam procedure from May 2015 to November 2015. Among them, only nineteen (19) patients were eligible for the study with characteristics as shown in table 1. The inclusion criteria are PSA level ≥ 4 ng/ml, with or without nodular palpable prostate from DRE. Exclusion criteria are

not cooperative/ fail to do MRI procedure, patients with MRI contra indications, claustrophobia and fail to provide histopathology result after mp-MRI procedure.

Examination using single calibrated MRI unit 1.5 Tesla (Avanto Fit), gradient strength 45 mT/m, slew rate 200 T/m/s, b value of 0, 50, 500, 800, 1000, 1500, 2000 (high b-value) with a pelvic phased array surface coil and endorectal coil.

Table 1. Patients' Characteristics

No	Initial	Age	PSA	Nodule (DRE)	Biopsy finding
1	JLA	83	25.28	-	benign
2	WSA	65	100	+	malignant
3	RGU	68	10.76	-	malignant
4	RHA	67	5.22	-	benign
5	IRU	72	10.99	-	benign
6	RSO	63	38.81	-	malignant
7	CAK	69	10.11	-	benign
8	JIS	67	5.3	-	malignant
9	RTU	77	28.6	-	malignant
10	BSU	68	4.49	-	malignant
11	JKH	65	64.26	-	malignant
12	SUH	74	5.77	-	malignant
13	CHA	68	32.02	-	malignant
14	BAT	59	10.98	-	malignant
15	HTO	73	11.3	-	malignant
16	RUD	73	100	-	malignant
17	HNA	70	110.69	-	malignant
18	FBO	75	9.5	-	malignant
19	JPA	65	8.95	-	benign

Below is the specified parameter of the MRI that was used in this research.

Table 2. Parameter of mp-MRI

No	Sequence and imaging plane	Sequence type	TR (msec)	TE (msec)	Field of View (mm)	Matrix	In-Plane Resolution (mm ²)	Slice Thickness (mm)	Flip Angle (degree)	Average / b value	slice spacing (mm)	Phase Encoding Direction	Scan Duration (min:sec)
1	T2-weighted Axial	Turbo Spin Echo	7000	112	160	330 x 384	0.4 x 0.4	4	160	2	0	R-L	3:39
2	T2-weighted Sagittal	Turbo Spin Echo	7000	119	160	266 x 320	0.5 x 0.5	4	160	2	0	H-F	2:57
3	T2-weighted Coronal	Turbo Spin Echo	7000	98	160	298 x 320	0.5 x 0.5	4	160	2	0	R-L	2:57
4	DWI Axial	Echo Planar Spin Echo	3600	86	200	48 x 140	1.4 x 1.4	4	-	0, 50, 500, 800, 1000, 1500, 2000	0	R-L	9:16

TR, repetition time; TE, echo time; DWI, Diffusion Weighted Imaging; msec, millisecond; mm, millimeter; min, minute; sec, second; R, Right; L, Left; H, Head; F, Feet

Prior to the exam, patients were given Hyoscine- N- butylbromide injection to reduce rectal spasm and peristaltic. An endorectal prostate coil (Sentinelle Medical, Siemens AG) was inserted using analgesic gel to avoid pain. The mp-MRI images were evaluated by a radiologist experienced with MRI and had been assessing prostate mp-MRI for at least 5 years. After the examination, patients were asked to bring the result to the urologist, to get further assessment for work-up, therapy or follow up procedures. All the patients were contacted by researcher for further follow

up regarding the biopsy results and asked to send the data.

The prostate is divided into peripheral zone, central zone and transitional zone with prostate anatomical map from Prostate Imaging Reporting and Data System (PIRADS) version 2 to point out the lesion location. This map can be used as biopsy guidance so that the biopsy will focus more in the suspicious areas. ⁽²⁰⁾

The category evaluation was based on Prostate Imaging Reporting and Data System (PIRADS) version 2.

- Assessment of T2Weighted Image (T2WI)

T2 images are used to differentiate central gland with peripheral gland, assess abnormalities within the gland and to evaluate seminal vesicle invasion, Extra Capsular Extension (ECE), and nodal involvement.

- Assessment of Diffusion-Weighted Imaging (DWI)

DWI reflects the random motion of water molecules and is a key component of the prostate mp-MRI exam. It should include an ADC map and ADC value in the setting of high b value (b value $\geq 1400 \text{sec/mm}^2$). The ADC map is a map of ADC values for each voxel in an image. MRI software setting automatically displayed ADC value when the cursor was placed at certain point, that is called Region Of Interest (ROI). The cursor has to be precisely located to acquire valid value with a reasonable diameter. After the MRI procedure, patients were sent back to the urologist along with the result for evaluation. Biopsies were done by experienced urologists and sent to

Pathology Anatomy Department to be analyzed by pathologists. The results were then analyzed using statistical test. As their data distribution was not normal, Mann Whitney U test was used as non-parametric test to analyze whether there was difference between malignant and benign prostate. ROC curve were built to define cut off points of MRI score and ADC value.

RESULTS

From the research flow below, there are 34 patients from 68 patients who have not needed biopsy for the meantime, 50% of the sample populations avoided the unnecessary biopsy and were subjected to active surveillance instead of biopsy since they only had history of PSA elevation, which is not specific for prostate cancer. Unfortunately of all patients who needed to undergo biopsy, only 19 patients were willing to do the procedure. The rests (44.12%) refused to do biopsy because mostly were afraid to do the invasive procedure.

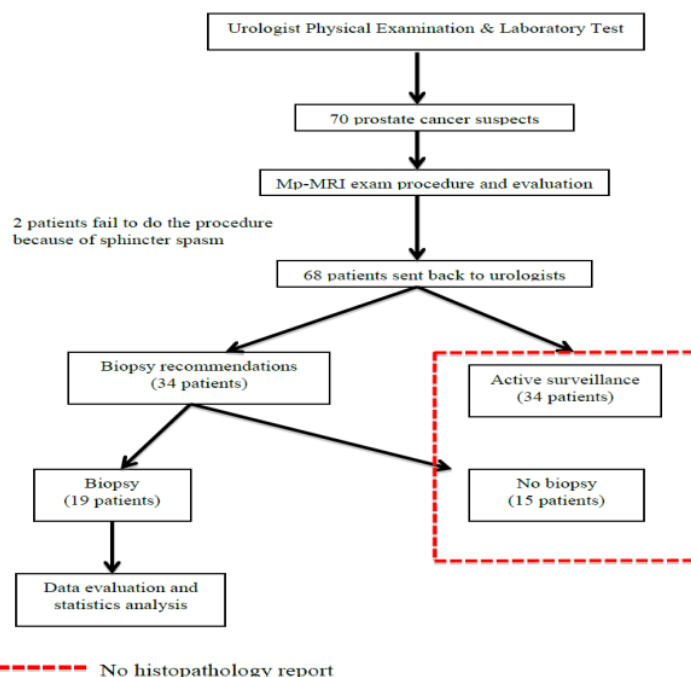


Figure 1. Research Work Flow

There were 12 patients out of 19 (63.16%) who came out positive for prostate cancer from histopathology report. More patients (58.3%) had multifocal lesions, while 68.75% lesions were located in peripheral zone.

Table 3. Result Description

	Median	Min:Max	p
Malignant mp-MRI score	9	8:10	0.005
Benign mp-MRI score	2	2:9	
Malignant ADC value	0.542	0.339:0.768	0.022
Benign ADC value	0.987	0.450:1.569	

MRI median score was 2 for benign prostate and 9 for prostate cancer, while

ADC median value for benign and prostate cancer respectively was $0.987 \times 10^{-3} \text{ mm}^2/\text{s}$ and $0.542 \times 10^{-3} \text{ mm}^2/\text{s}$. Statistically significant differences were identified between MRI score for benign and malignant prostate ($p=0.005$, $p<0.05$) also between ADC value for benign and malignant prostate ($p=0.022$, $p<0.05$).

Knowing that there were significant differences between malignant and benign score, there should be cut off points of the MRI score and ADC value to differentiate prostate cancer and benign prostate.

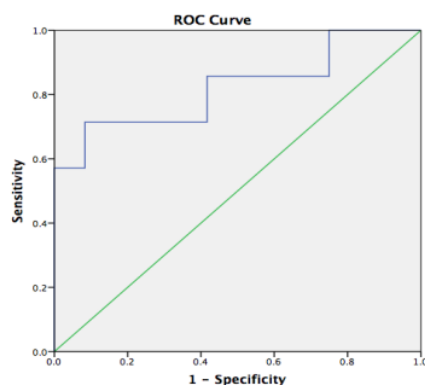
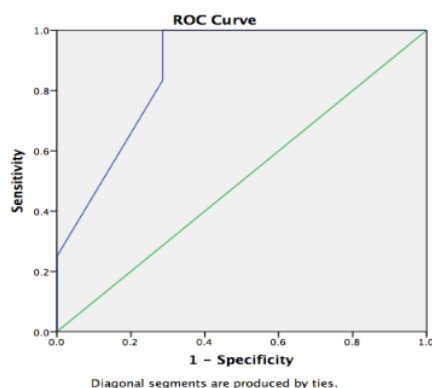


Figure 2. ROC mp-MRI (left) and ADC value (right)

Area Under the Curve (AUC) from the ROC was 0.869 for mp-MRI score and 0.821 for ADC value.

Table 4. Coordinate Points for mp-MRI Score

Malignancy if score \geq	Sensitivity	Specificity
1	100%	0%
4	100%	51%
7	100%	71.4%
8.5	83.3%	71.4%
9.5	25%	100%
11.5	0%	100%

From the coordinate points in table 4, we chose 7 as mp-MRI cut off score as it had the best sensitivity with an acceptable specificity. We also decided to use cut off value 0.684 for ADC with 71.4% sensitivity and 91.7% specificity.

DISCUSSION

There was a statistical significant difference between multiparametric MRI total score in benign prostate and malignant prostate, ADC value also had statistical significant difference between benign and malignant prostate. It means both parameters can be used to differentiate malignancy toward other non-malignant conditions. Multiparametric MRI total score that is bigger or equal than 7 indicates malignancy while score that is less than 7 suggests benign condition. As a complementary value, ADC value is used to confirm the finding from MRI score by measuring the ADC value of the lesion. ADC value less than $0.684 \times 10^{-3} \text{ mm}^2/\text{s}$ confirms malignant prostate. However, ADC value reference could only be used

with the same MRI parameter as shown in this research because the value is widely varied and dependent in many internal also external factors. ADC value depends on many factors such as magnetic strength difference of the MRI device used.⁽²¹⁾ Tamada et al. mentioned that it also influenced by biologic difference in human at different age.⁽²²⁾ The choice of b-value can significantly affect ADC value estimation. ADC value cut off points from other studies or literature can't be adapted instantly and need caution regarding the b value used.⁽²³⁾ Mean ADC value for cancer Region Of Interest (ROI) and non-cancer ROI, respectively, were $1.11 \pm 0.41 \times 10^{-3}$ and $1.68 \pm 0.40 \times 10^{-3}$ mm²/second ($p < 0.01$).⁽¹⁶⁾

It is a better imaging modality in detecting prostate cancer locally compared to ultrasound, and CT-scan. It can be done without intravenous contrast administration to avoid discomfort in patients and allergic reactions. MRI without contrast injection also can be done to patients with renal impairment.

DRE only has 77.6% sensitivity, 36.7% specificity in detecting prostate cancer.⁽²⁴⁾ PSA, which has been widely recognized as prostate cancer tumor marker, is not cancer specific.⁽²⁵⁾ Positive predictive value is 20.6% for PSA from 4-10 ng/mL, and 32.7% for those with PSA from 10-20 ng/mL.⁽²⁶⁾ Transrectal Ultra Sound (TRUS) is used to measure the volume of prostate gland, with the diagnostic accuracy is as low as DRE. TRUS has been used for local staging of prostate cancer in some studies but was generally considered insufficient; therefore TRUS alone without biopsy has limited value in prostate cancer detection.⁽²⁷⁾

TRUS is able to find hypo echoic lesion during biopsy, even though it is more useful for prostate margin landmark, despite that biopsy will still be done systematically without knowing the exact location of the lesion. We have to argue that this kind of "blind" biopsy is somehow inappropriate. It is also against the medical principle of

primum non nocere, especially for cancer patients whom psychologically fragile and prone to biopsy bad myths in society. Similar opinion was expressed by Dickinson et al who stated that the current diagnostic pathway for prostate cancer remains suboptimal because TRUS guided biopsy as the current standard is conducted blindly to cancer location within the prostate. Men were subjected to TRUS guided biopsies based on elevated PSA only, that led to some probably unnecessary biopsies. This rendered prostate cancer diagnosis a health state that was largely determined by chance, even worse.^(11,28) Even with systematic biopsy that has increased from 12 cores to 20 cores, there is still many chances of missed lesion because the lesion can be anywhere outside the "chart" coverage. From one study, it was stated that TRUS-guided biopsy only found hypoechoic lesion in 88 out of 400 patients (22%) and only 20 patients were proven prostate cancer. Nevertheless, no visible lesion from the ultrasound didn't mean that it was cancer free, there were 25 prostate cancer patients from 312 patients without any lesions visible from ultrasound.⁽²⁸⁾ Djavan et al. also found in their study previously that the initial biopsy was 22% positive for prostate cancer and at least 10% negative initial biopsy was found positive later in the repeated biopsy.⁽²⁹⁾ Patients with negative biopsy result but persistent or increasing PSA levels need to do repeat biopsy, which will have negative impact in their quality of life. Repeated biopsy causes more harm and decreasing accuracy compared to repeated MRI. The cancer detection rate was 50.5% in patients with one series of prior negative biopsy findings and 42.3%, 47.6%, 33.3%, and 40% in patients with two, three, four and five series of negative biopsy findings, respectively.⁽³⁰⁾ Targeted biopsy to a lesion seen by MRI can increase detection of significant cancers and improve evaluation of their grade and size. This strategy will also mean that the detection of insignificant cancers (micro foci detected by chance during systematic biopsy) will decrease,

since mp-MRI do not give rise to suspicion, the indications for unnecessary biopsy would be reduced. This strategy also reduces the number of biopsies to be performed by resorting solely to targeted biopsies.⁽¹⁴⁾

A guideline on prostate cancer from European Association of Urology year 2015 mentioned a controversy as some authors proposed mp-MRI as a triage test for biopsy candidate to increase detection of aggressive cancers and reduce over detection of non-significant foci. MRI is done before biopsy, beside to locate the lesion also to avoid MRI artifact due to biopsy. The alternative of waiting 2-4 months after biopsy is likely to be unacceptable and impractical for patients and clinicians.^(31,32) From one systematic review, others concluded that there was not enough evidence to recommend mp-MRI before a first set of negative biopsy. The combination of systematic and targeted biopsy schemes provide the highest detection rate in all studies, suggesting that this approach is the best option, if detection rate is considered the main outcome.⁽³³⁾

From this study, we have experienced that there were some patients who refused to do biopsy or repeat biopsy. This might be a relevant condition of people nowadays that would prefer non-invasive methods rather than invasive procedures if possible, mostly because of fear, hesitate against the side effects it may cause and biopsy bad myths.

De Rooij *et al.* compared the quality of life (QoL) and health care costs for the systematic TRUS-guided biopsy strategy and the imaging-based strategy where MRI and directed MR-guided biopsies were performed. Their results suggested comparable healthcare costs in the two strategies but an improved quality of life (QoL) in the imaging arm. The benefits in QoL are decrease in overdiagnosis and overtreatment in the imaging arm.⁽³⁴⁾ Nevertheless, urologists are the ones responsible for decision making, because there are different risks each patient is imposed to, which they need to make

clinical judgement for each case regarding the MRI timing, and whether to do biopsy or active surveillance based on different kind of perspectives, studies and views considered. On the other hand, Computed Tomography (CT) is not recommended for local prostate imaging. Although CT continues to be widely used in patients with newly diagnosed prostate cancer, it has virtually no role in prostate cancer detection or primary tumor staging. On CT scans, intraprostatic anatomy is not well demonstrated. The poorness of quality make it hard to be able to identify prostate lesion clearly, unless in locally advanced stage. The major role of CT is in the nodal staging of prostate cancer, for which it is limited.⁽²⁷⁾ Reported CT sensitivity for the detection of lymph node metastases varies, but it is typically in the range of 36%.⁽³⁵⁾

This research proved that this simpler prostate mp-MRI fulfilled the expectation to be able assist prostate cancer detection and identify the need of biopsy. Mp-MRI imaging procedure is also simple and safe without the use of contrast and without radiation exposure, which support repeated use without any harm. With MRI score 7 as the cut off point for prostate malignancy, the sensitivity is 100 % and specificity is 71.4 %. As for ADC value, cut off point of ≥ 0.684 indicates benign prostate condition with 91.7% specificity and 71.4% sensitivity. ADC value was lower than those mentioned in the literature, both in benign or malignant prostate tissue. It was very possible to have different values, due to different settings, such as b value, different magnetic strength, etc., so this value is only valid for the same MRI device specifications used in this study.

We suggest further research with bigger number of sample and correlation with prostate specific biomarker for widely accepted clinical use.

CONCLUSIONS

This simpler multi-parametric MRI can be utilized to differentiate prostate cancer with benign prostate. Cut off of 7 in

mp-MRI score has good sensitivity and specificity while ADC could be used as a complementary value to support the result. Further studies are needed to validate our findings, also more research to elaborate this study with prostate specific biomarker to improve the diagnostic accuracy.

23

REFERENCES

1. International Agency for Research on Cancer. Prostate Cancer Estimated Incidence, Mortality and Prevalence Worldwide in 2012 [Internet]. World Health Organization. 2016. p. 4. Available from: http://globocan.iarc.fr/Pages/fact_sheets_ca29r.aspx
2. Nelson WG, Carter HB, Deweese TL, Antonarakis ES, Eisenberger MA. Prostate Cancer [Internet]. Fifth Edit. Abeloff's Clinical Oncology. Elsevier Inc.; 2014. 3453-1496.e9 p. Available from: <http://dx.doi.org/10.1016/B978-1-4557-3855-7.00084-9>
3. National Institute for Health and Clinical Excellence. Prostate cancer: diagnosis and management. 2014.
4. 35roll PR, Kellogs JP, Androile G, Banson RR, Castle EP, Catalona WJ, et al. Prostate 16ncer Early Detection version 2 [Internet]. National Comprehensive Cancer Network. 2016 [cited 2016 Dec 13]. Available from: https://www.nccn.org/professionals/physician_gls/pdf/prostate_detection.pdf
5. Carter B, Albertsen P, Barry M, Etzioni R, Freedland S, Greene K, et al. Early Detection of Prostate Cancer: Aua Guideline [Internet]. American Urological Association Education and Research. 2013. 25 1–28. Available from: <https://www.auanet.org/common/pdf/education/clinical-guidance/Prostate-Cancer-Detection.pdf>
6. Mottet N, Bellmunt J, Briers E, Bergh RCN van den, Bolla 25 Casteren NJ van, et al. Guidelines on Prostate Cancer [Internet]. European Association of Urology. 2037 p. 1–137. Available from: http://www.uroweb.org/fileadmin/tx_eauguidelines/2005/Pocket/Prostate_Cancer.pdf
7. Rahardjo D, Pakasi LS, Birowox P, Gardian STK, Himawan S. Possible factors influencing high serum Prostate-specific Antigen (PSA) in Indonesian patients with Benign Prostatic Hyperplasia (BPH). Med 19ndones. 2001;10(1):22–8.
8. Mochtar CA, Andika RS. The value of prostate-specific antigen in Asia. Ther Adv 10bl. 2010;2(2):77–83.
9. Homma Y, Kawabe K, Tsukamoto T, Yamanaka H, Okada K, Okajima E, et al. Epidemiologic Survey of Lower Urinary Tract Symptoms in Asia and Australia Using the International Prostate 22mptom Score. Int J Urol [Internet]. 1997;4(1):40–6. Available from: <http://www.ncbi.nlm.nih.gov/pubmed/9179620>
10. Mohler JL, Armstrong AJ, Bahnson RR, D'Amico AV, Davis BJ, A.Eastham J, et al. NCCN Clinical Practice Guidelines in Oncology: Prostate Cancer. Prostate Cancer version 3. 2016;551–62.
11. Dickinson L, Ahmed HU, Allen C, Barentsz JO, Carey B, Futterer JJ, et al. Clinical applications of multiparametric MRI within the prostate cancer diagnostic pathway. Urol Oncol Semin Orig Investig. 2013;31(3):285–7.
12. Haarer CF, Gopalan A, Tickoo SK, Scardino PT, Eastham JA, Reuter VE, et al. Prostatic Transition Zone Directed Needle Biopsies Uncommonly Sample Clinically Relevant Transition Zone Tumors. J Urol [Internet]. Elsevier Inc.; 2009;182(4):1337–41. 52 Available from: <http://dx.doi.org/10.1016/j.juro.2009.06.042>
13. Presti JC. Prostate Biopsy : Current Status 15 Limitations. 2007;9(3):93–8.
14. Villers a, Marliere F, Ouzzane a, Puech P, Lemaître L. MRI in addition to or as a substitute for prostate biopsy: the clinician's point of view. Diagn Interv Imaging [Internet]. Elsevier 33asson SAS; 2012; 93(4):262–7. Available from: <http://www.ncbi.nlm.nih.gov/pubmed/22465789>
15. Hambrock T, Somford DM. Relationship between Apparent Diffusion Coefficients at 3 . 0-T MR Imaging and Gleason Grade in Peripheral Zone Prostate Cancer 1 Purpose : Methods : 45ults. Imaging [Internet]. 2011;259(2):453–61. Available from: <http://www.ncbi.nlm.nih.gov/pubmed/2140643>
16. Sato C, Naganawa S, Nakamura T, Kumada H, Miura S, Takizawa O, et al. Differentiation of noncancerous tissue and cancer lesion by apparent diffusion

- coefficient values in transition and peripheral zones of the prostate. *J Magn Reson Imaging*. 2005;21(3):258–62.
17. Matsumoto Y, Kuroda M, Matsuya R, Kato H, Shibuya K, Oita M, et al. In vitro experimental study of the relationship between the apparent diffusion coefficient and changes in cellularity and cell morphology. *Oncol Rep*. 2009;22:641–8.
18. Rosenkrantz AB. MRI of the Prostate. *Lippincott Williams & Wilkins*; 2017. 226 p.
19. Tan CH, Hobbs BP, Wei W, Kundra V. Dynamic Contrast-Enhanced MRI for the Detection of Prostate Cancer: Meta-Analysis. *AJR AM J Roentgenol*. 2015;274(4):W439–448.
20. American College of Radiology Working Group. PI-RADS Prostate Imaging – Reporting and Data System. American College of Radiology. 2015.
21. Malayeri AA, El Khoul RH, Zaheer A, Jacobs MA, Corona-Villalobos CP, Kamel IR, et al. Principles and Applications of Diffusion-weighted Imaging in Cancer Detection, Staging, and Treatment Follow-up. *Radiographics*. 2011;31(6):1773–91.
22. Tamada T, Sone T, Toshimitsu S, Imai S, Jo Y, Yoshida K, et al. Age-related and zonal anatomical changes of apparent diffusion coefficient values in normal human prostatic tissues. *J Magn Reson Imaging*. 2008;27(3):552–6.
23. Peng Y, Jiang Y, Antic T, Sethi I, Schmid-Tannwald C, Eggen S, et al. Apparent diffusion coefficient for prostate cancer imaging: Impact of b values. *Am J Roentgenol*. 2014;202(3).
24. Aslan G, Iler B, Cimen S, Goktay Y, Celebi I, Tuna B, et al. The Performance of Abnormal Digital Rectal Examination for the Detection of Prostate Cancer at Stratified Prostate Specific Antigen Levels. *Open J Urol* [Internet]. 2011;1(4):67–71. Available from: <http://www.scirp.org/journal/PaperInformation.aspx?PaperID=8221&#act>
25. Cattarino S, Ciccariello M. The dilemma of early diagnosis for a clinically relevant prostate cancer: The role of urologist. *Multidiscip Manag Prostate Cancer Role*. 2013;43–55.
26. Vukotic V, Cerovic S, Kozomara M, Lazic M. The predictive value of PSA in diagnosis of prostate cancer in non-screened population. *Acta Chirurgica Iugosl*. 2005;54(4):81–6.
27. Hricak H, Choyke PL, Eberhardt SC, Leibel SA, Scardino PT. Imaging prostate cancer. *Radiology* [Internet]. 2007;243(1):28–53. Available from: <http://www.ncbi.nlm.nih.gov/pubmed/23122947>
28. Shahab AA, Soebadi DM, Djatisoesanto W, Hardjowijoto S, Soetojo S, Hakim L. Prostate-specific antigen and prostate-specific antigen density cutoff points among Indonesian population suspected for prostate cancer. *Prostate Int* [Internet]. 2013;1(1):23–30. Available from: <http://dx.doi.org/10.12954/PI.12003>
29. Djavan B, Zlotta a, Remzi M, Ghawidel K, Basharkhah a, Schulman CC, et al. Optimal predictors of prostate cancer on repeat prostate biopsy: a prospective study of 1,051 men. *J Urol* [Internet]. 2000;163(4):1144–8–9. Available from: <http://www.ncbi.nlm.nih.gov/pubmed/10737484>
30. Cornelis F, Al E, François Cornelis, MD, Gérald Rigou, MD, Yann Le Bras, MD, Xavier Coutouly, MD, Régis Hubrecht, MD, Mokrane Yacoub, MD, Gilles Pasticier, MD, Grégoire Robert, MD, PhD, Nicolas Grenier MD. Real-time Contrast-enhanced Transrectal US-guided Prostate Biopsy: Diagnostic Accuracy in Men with Previously Negative Biopsy Results and Positive MR Imaging Findings. *Radiology*. 2013;269(1):1–8.
31. Ahmed HU, Kirkham A, Arya M, Illing R, Freeman A, Allen C, et al. Is it time to consider a role for MRI before prostate biopsy? *Nat Rev Clin Oncol* [Internet]. 2009;6(4):197–206. Available from: <http://www.ncbi.nlm.nih.gov/pubmed/19333226>
32. Moore CM, Robertson NL, Arsanious N, Middleton T, Villers A, Klotz L, et al. Image-Guided Prostate Biopsy Using Magnetic Resonance Imaging – Derived Targets : A Systematic Review. *Eur Urol*. 2013;63:125–40.
33. van Hove A, Savoie PH, Maurin C, Brunelle S, Gravis G, Salem N, et al. Comparison of image-guided targeted biopsies versus systematic randomized biopsies in the detection of prostate cancer: A systematic literature review of well-designed studies. *World J Urol*. 2014;32(4):847–58.

34. De Rooij M, Crienien S, Witjes JA, Barentsz JO, Rovers MM, Grutters JPC. ⁴⁷Effectiveness of Magnetic Resonance (MR) ⁵⁷imaging and MR-guided targeted biopsy versus systematic transrectal ultrasound-guided biopsy in diagnosing prostate cancer: A modelling study from a health care perspective. Eur Urol [Internet]. European Association of Urology; 2014;66(3):430–6. Available from: <http://dx.doi.org/10.1016/j.eururo.2013.12.012>
35. Wolf JS, Cher M, Dall'era M, Presti JC, Hricak H, Carroll PR. The use and accuracy of cross-sectional imaging and fine needle aspiration cytology for detection of pelvic lymph node ²⁵metastases before radical prostatectomy. J Urol [Internet]. 1995;153(3 Pt 2):993–9. Available from: <http://www.ncbi.nlm.nih.gov/pubmed/7853590>

How to cite this article: Setiawan T, Murtala B, Bel⁵³min AF et al. Score of multi parametric MRI: T2 and DWI to assist prostate cancer detection. *Int J Health Sci Res.* 2017; 7(8):92-101.

Score of Multi Parametric MRI: T2 and DWI to Assist Prostate Cancer Detection

ORIGINALITY REPORT

21%

SIMILARITY INDEX

16%

INTERNET SOURCES

16%

PUBLICATIONS

15%

STUDENT PAPERS

PRIMARY SOURCES

1	www.frontiersin.org Internet Source	1%
2	Submitted to University of Cumbria Student Paper	1%
3	Vincenzo Scattoni, Carmen Maccagnano. "Chapter 53 US Contrast Media in Prostatic Disease", Springer Science and Business Media LLC, 2017 Publication	1%
4	content.sciendo.com Internet Source	1%
5	iranjradiol.com Internet Source	1%
6	www.elsevier.es Internet Source	1%
7	Submitted to Trinity College Dublin Student Paper	1%
8	Submitted to University of Queensland Student Paper	

1 %

9

Submitted to RMIT University

Student Paper

1 %

10

www.pubmedcentral.nih.gov

Internet Source

1 %

11

es.scribd.com

Internet Source

1 %

12

Hambrock, T., D. M. Somford, H. J. Huisman, I. M. van Oort, J. A. Witjes, C. A. Hulsbergen-van de Kaa, T. Scheenen, and J. O. Barentsz.

"Relationship between Apparent Diffusion Coefficients at 3.0-T MR Imaging and Gleason Grade in Peripheral Zone Prostate Cancer", Radiology, 2011.

Publication

1 %

13

Prativa Sahoo, Russell Rockne, Jung Alexander, Pradeep K Gupta, Rakesh K Gupta. " Synthetic apparent diffusion coefficient for high -value diffusion weighted MRI in Prostate ", Cold Spring Harbor Laboratory, 2019

Publication

1 %

14

academic.oup.com

Internet Source

1 %

15

Soroush Rais-Bahrami, Baris Turkbey, Kinzya B. Grant, Peter A. Pinto, Peter L. Choyke. "Role

1 %

of Multiparametric Magnetic Resonance Imaging in the Diagnosis of Prostate Cancer", Current Urology Reports, 2014

Publication

16	synapse.koreamed.org Internet Source	1 %
----	-----------------------------------------------------------------------------------	-----

17	www.thno.org Internet Source	<1 %
----	-------------------------------------------------------------------	------

18	wwwold.med.bg.ac.rs Internet Source	<1 %
----	---------------------------------------------------------------------------------	------

19	s3-eu-west-1.amazonaws.com Internet Source	<1 %
----	-----------------------------------------------------------------------------------------------	------

20	Kyo Chul Koo, Jin Seon Cho, Woo Jin Bang, Seung Hwan Lee et al. "Cancer-Specific Mortality Among Korean Men with Localized or Locally Advanced Prostate Cancer Treated with Radical Prostatectomy Versus Radiotherapy: A Multi-Center Study Using Propensity Scoring and Competing Risk Regression Analyses", Cancer Research and Treatment, 2018 Publication	<1 %
----	------------------------------------------------------------------------------------------------------------------------------------------------------------------------------------------------------------------------------------------------------------------------------------------------------------------------------------------------------------------	------

21	Submitted to Lebanese University Student Paper	<1 %
----	---------------------------------------------------	------

22	aidsinfo.nih.gov Internet Source	<1 %
----	---------------------------------------------------------------------------	------

23	www.jpmmh.org Internet Source	<1 %
24	Submitted to University of Leicester Student Paper	<1 %
25	uro20141.blogspot.com Internet Source	<1 %
26	Submitted to Canterbury Christ Church University Student Paper	<1 %
27	Submitted to Monash University Student Paper	<1 %
28	www.spandidos-publications.com Internet Source	<1 %
29	Nelson, William G., and Kenneth J. Pienta. "Molecular Mechanisms of Prostate Cancer Progression After Castration", Current Clinical Urology, 2014. Publication	<1 %
30	Submitted to Turun yliopisto Student Paper	<1 %
31	Submitted to Higher Education Commission Pakistan Student Paper	<1 %
32	www.researchgate.net Internet Source	<1 %

33	Submitted to University of Birmingham Student Paper	<1 %
34	corrillos.com.co Internet Source	<1 %
35	implementationscience.biomedcentral.com Internet Source	<1 %
36	jhs.mazums.ac.ir Internet Source	<1 %
37	Submitted to University of New England Student Paper	<1 %
38	bmccancer.biomedcentral.com Internet Source	<1 %
39	ijsurgery.com Internet Source	<1 %
40	K. Sklinda, M. Frączek, B. Mruk, J. Walecki. "Normal 3T MR Anatomy of the Prostate Gland and Surrounding Structures", Advances in Medicine, 2019 Publication	<1 %
41	Submitted to Universitas Airlangga Student Paper	<1 %
42	Submitted to University of Stellenbosch, South Africa Student Paper	<1 %

43

Internet Source

<1 %

44

Michael A. Jacobs. "Diffusion-Weighted Imaging With Apparent Diffusion Coefficient Mapping and Spectroscopy in Prostate Cancer", Topics in Magnetic Resonance Imaging, 11/2008

Publication

<1 %

45

www.cambridge.org

Internet Source

<1 %

46

Giannarini, G.. "Potential and Limitations of Diffusion-Weighted Magnetic Resonance Imaging in Kidney, Prostate, and Bladder Cancer Including Pelvic Lymph Node Staging: A Critical Analysis of the Literature", European Urology, 201202

Publication

<1 %

47

Raj Satkunasivam, Laurence Klotz. "Chapter 4 Low-Risk Prostate Cancer in North America: Rationale, Uptake, and Limitations of Active Surveillance and Opportunities for Focal Therapy", Springer Science and Business Media LLC, 2017

Publication

<1 %

48

"Male Infertility and Sexual Dysfunction", Springer Science and Business Media LLC, 1997

Publication

<1 %

49

Angelika Borkowetz, Johannes Bruendl, Martin Drerup, Jonas Herrmann, Hendrik Isbarn, Burkhard Beyer. "Multicenter evaluation of guideline adherence for pelvic lymph node dissection in patients undergoing open retropubic vs. laparoscopic or robot assisted radical prostatectomy according to the recent German S3 guideline on prostate cancer", World Journal of Urology, 2018

Publication

<1 %

50

Ryogo Minamimoto, Hiroji Uemura, Futoshi Sano, Hideyuki Terao et al. "The potential of FDG-PET/CT for detecting prostate cancer in patients with an elevated serum PSA level", Annals of Nuclear Medicine, 2010

Publication

<1 %

51

Watanabe, Yuji, Masako Nagayama, Tohru Araki, Akito Terai, Akira Okumura, Yoshiki Amoh, Takayoshi Ishimori, Satoru Nakashita, and Yoshihiro Dodo. "Targeted biopsy based on ADC map in the detection and localization of prostate cancer: A feasibility study", Journal of Magnetic Resonance Imaging, 2012.

Publication

<1 %

52

amb-express.springeropen.com

Internet Source

<1 %

53

jurnal.ugm.ac.id

Internet Source

<1 %

54

Claudia Testa, Riccardo Schiavina, Raffaele Lodi, Eugenio Salizzoni et al. "Accuracy of MRI/MRSI-based transrectal ultrasound biopsy in peripheral and transition zones of the prostate gland in patients with prior negative biopsy", NMR in Biomedicine, 2010

Publication

<1 %

55

Servet Tatli. "Local staging of rectal cancer using combined pelvic phased-array and endorectal coil MRI", Journal of Magnetic Resonance Imaging, 04/2006

Publication

<1 %

56

Hyo Serk Lee. "Comparative Analysis of Outcomes after Transurethral Resection of the Prostate according to Prostate Shape Shown by Transrectal Ultrasonography", Korean Journal of Urology, 2010

Publication

<1 %

57

Keyanoosh Hosseinzadeh, Samuel David Schwarz. "Endorectal diffusion-weighted imaging in prostate cancer to differentiate malignant and benign peripheral zone tissue", Journal of Magnetic Resonance Imaging, 2004

Publication

<1 %

Exclude bibliography Off